



Available online through

www.jbsoweb.com

ISSN 2321 - 6328

## Research Article

### EFFECTIVE MANAGEMENT OF DUSHTA VRANA WITH PRAKSHALAN KARMA: A CASE REPORT

Parvinder Singh <sup>1\*</sup>, Vasudeva Reddy <sup>2</sup>, Ashutosh Chaturvedi <sup>3</sup>

<sup>1</sup> PG Scholar, Sri Jayendra Saraswathi Ayurveda College, Chennai (Department of Ayurveda), Sri Chandrashekharendra Saraswathi Viswamahavidyalaya Kanchipuram, India

<sup>2</sup> HOD Professor, Department of Shalya Tantra, Sri Jayendra Saraswathi Ayurveda College, Chennai (Department of Ayurveda), Sri Chandrashekharendra Saraswathi Viswamahavidyalaya Kanchipuram, India

<sup>3</sup> Assistant Professor of Panchakarma, Sri Jayendra Saraswathi Ayurveda College, Chennai (Department of Ayurveda), Sri Chandrashekharendra Saraswathi Viswamahavidyalaya Kanchipuram, India

\*Corresponding Author Email: parvinder33707@gmail.com

Article Received on: 15/09/22 Accepted on: 15/10/22

DOI: 10.7897/2321-6328.105167

#### ABSTRACT

A condition where the tissues in the body are destroyed selectively and after repair, discoloration occurs leaving a scar for a lifetime is known as a wound or Vrana. The management and healing process of wounds regardless of their tissue types or the incite injury are described in Ayurveda. Through this knowledge the surgeons are able to manipulate wounds which helps in achieving optimal results in a short period. Non healing ulcers can be correlated with Dushta Vrana in Ayurveda. The word prakshalana means washing. Prakshalana karma is a procedure where medicated decoction is poured over the affected area. In dushta Vrana, this procedure helps in cleaning the wound from the dirt, infection, and germs. It also hastens the wound healing process as it helps in quick renewal of the cells. In the present case report of dushta vrana, a detailed history of the patient with all necessary clinical and physical examination and laboratory investigations were carried out. The patient was admitted in the hospital and treated with external procedure like prakshalana karma along with other internal medications. The wound showed maximum improvement after the Prakshalana karma with improvement in other symptoms as well as the healing of the wound.

**Keywords:** Dushta Varana, Jaytadi Tailam, Non-healing wound, Scar, Triphala Kshayam, Wounds.

#### INTRODUCTION

Sushruta has defined Vrana as a phenomenon which consumes the tissue and on healing leaves "Vrana Vastu" i.e, permanent scar tissue<sup>1</sup>, Vrana is seen as debilitating and scaring disorder usually seen affecting the human being at any age .Vrana is the condition associated with Dhatu Nashta (destruction of tissue).

Acharya Sushruta has described specific types of wounds which by any external or internal factors have reduced to a condition where healing is delayed or absent under Dusta Vrana.

Acharya Charaka has mentioned that the Vrana which produces foul smell, has lost its normal colour and produces excessive discharge with pain is Dushta Vrana. According to Madhavacharya, Dushta Vrana is that which is chronic in nature, elevated from the surface, discharges pus and impure blood with foul smell and having opposite characters of Shuddha Vrana.<sup>2</sup>

Wound healing – In the context of wound healing two terms should be understood

1. Regeneration - which means replacement of lost tissue by tissue similar in type. This occurs due to proliferation of surrounding undamaged specialized cells.
2. Repair – which means replacement of lost tissue by granulation tissue, followed by fibrosis and scar tissue formation. This occurs when the surrounding specialized cells

do not possess the capacity to proliferate e.g., neurons and muscles of destruction of tissue to such an extent that proliferation of the surrounding undamaged cell cannot make good the loss<sup>3</sup>.

#### CASE REPORT

**Type of study** – Observational single case design.

**Study Centre** – Sri Jayendra Saraswathi Ayurveda College and Hospital, Nazarathpethai, Chennai.

#### History of Present Illness

A 42-year-old married female patient presents with the complaint of a non-healing wound in the right lower leg for 4 months. The patient was apparently normal before 6 months. Then she developed pain in the lower leg followed by a small wound near the medial malleolus which increased in size and did not heal in spite of topical treatment. She received treatments from various hospitals but had no improvement in the symptoms. She has no history of hypertension, diabetes, tuberculosis, or any other major illness. Hence, she came to our hospital for further treatment.

Written informed consent of the patient was taken before initiating the procedure on the patient.

### Family History

Her mother is a known case of type 2 diabetes mellitus for 8 years.

### Personal History

Diet – Mixed  
 Appetite – Regular  
 Sleep – Disturbed  
 Bowels – Constipated (once in 2 days)  
 Micturition – Normal (4-5 times/ day)  
 Habits – Tea (4-5 cups/ day)  
 Addiction - None

### General Examination

**Table 1: General examination**

Blood pressure	120/80 mmHg
Respiratory rate	120/bpm
BMI	29.4 kg/m <sup>2</sup>
Edema	Bilateral lower legs
Icterus	Absent
Pulse rate	72/bpm
Height	5 feet 3 inches
WHR	-
Nails	Normal
Lymph nodes	Normal
Heart rate	72/bpm
Weight	62 kg
Pallor	Absent
Cyanosis	Absent
Temperature	36.8 degree C

### Local Examination

Ulcer was seen on inside the finger of left legs, with itching and pain, dryness is there, when we touch the fingers she feels pain, irregular margin of ulcer is seen and tenderness was also present with surrounding induration and local rise in temperature, local lymph node were not involved.

### Systemic Examination

CVS: No chest pain.  
 RS: No shortness of breath, no dyspnea.  
 GIT: Constipation.  
 CNS: No headache, no weakness, no radiating pain.  
 Musculoskeletal:  
 Other Findings:  
 Site: Right lower leg has a wound which is small in size with well-defined edges and granulated surrounding tissue. Tenderness present at the site region.

### Nidana

Dosha – Kapha vata  
 Dushyas involved – Mamsa, medas, asthi  
 Lakshanas – Non-healing wound in the right lower leg

**Rog Marga:** Bahya roga marga

### Dashavidha Pariksha

**Table 2: Dashavidha pariksha**

Dashavida pariksha	Interpretations
Pakruti	Kapha vata
Vikruti	Pitta kapha
Sara	Twak rakta
Samhanan	Madhyam
Pramana	Madhyam
Satmya	Vyamisra
Satva	Madhyam
Vaya	Madhyam
Ahara shakti	Madhyam
Vihara shakti	Madhyam

### Astavidha Pareeksha

**Table 3: Astavidha pariksha**

Astavidha pariksha	Interpretations
Nadi	Kapha vata
Mala	Shushka
Mutra	Alpa
Jihwa	Nirlipta
Shabda	Clear
Sparsha	Sheeta
Drika	Prakruta
Akriti	Madhyama

**Investigations:** Not done.

**Radiology:** Not done.

**Provisional Diagnosis:** Dushta Vranam.

### Treatment Plan

The patient was treated with both internal medications and external procedures.

#### Internal medication

1. Patola Katurohinyadi Kashaya 20 ml BD after food for 15 days.
2. Panch Tikta Ghrita Guggulu 1-0-1 after food for 15 days.
3. Patient was given Tiktaka Ghrita 1 tsp BD internally for 15 days after the completion of the procedure.

#### External treatment

The wound was cleaned and Prakshalana karma was administered with Triphala Kashaya. After Prakshalana karma, Jatyadi Tailam was locally applied, and dressing was done with sterile gauze and bandage once daily. This treatment plan was followed for a period of 6 weeks. The therapeutic procedure done is given in table 4.

**Table 4: Treatment procedure**

Treatment procedure	From	To	Number of days
Prakshalan karma with Triphala Kashaya + Wound dressing with Betadine sterile gauze once daily	02/06/2022	15/02/2022	14 days
Prakshalan karma with Triphala Kashaya + Jatyadi tailam local application + Dressing with sterile gauze once daily	16/06/2022	01/03/2022	14 days

## RESULTS

### Effect on Vrana Vedana (pain)

Patient pain and tenderness was completely reduced at the end of treatment. severe pain present at the initial stage and completely relief at the end of 1<sup>st</sup> week.

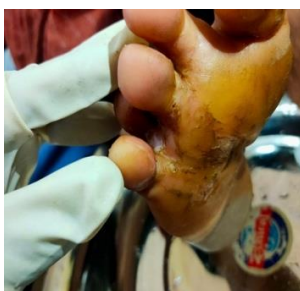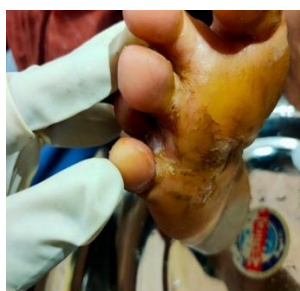
### Effect on Vrana Aakriti (structure)

At the end of the treatment, Vrana completely healed with minimal scar. Jatyadi Tailam, helped to reduce the wound size by promoting healing and the rate of contraction. The clinical features of Dushta Vrana were improved by the end of 1st week and the wound was healed completely at the end of 6<sup>th</sup> week leaving minimal scar. during a follow-up for a period of 15 days, no signs of recurrence were noticed.

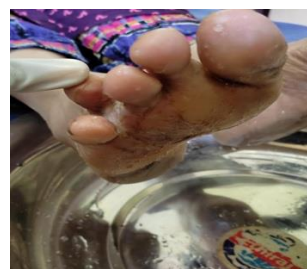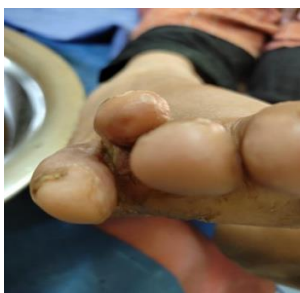The symptoms before and after treatment are mentioned in table 5.

**Table 5: Symptoms before and after treatment**

Before treatment	After treatment
Severe pain and tenderness present at the site region.	Tenderness completely stopped after 7 days of treatment.
Well defined edges of the wound.	
Granulation tissue present at the wound region.	
Scarring present.	Minimal scarring after 15 days of treatment.
Recurrence of the wound present.	No signs of recurrence occurred after treatment.



**Before Treatment**



**After Treatment**

## DISCUSSION

Sushruta emphasizes that before treating the Vrana, one should know the Moola<sup>4</sup> i.e., the causative factors (Vata, Pitta, Kapha, Sannipata, Rakta, Agantuja), Ashta Parigrahee i.e. Ashta Vrana Adhistaanas which includes Twak, Maamsa, Sira, Snaayu, Asthi, Sandhi, Koshta, Marma. It is also important to know the Pancha Lakshana Lakshitaha i.e., features of Vataja, Pittaja, Kaphaja, Sannipaataja and Agantuja Vranas as well as Varna, Sraava, Gandha, Vedana, Aakruti and also Shasti Upakramas for the proper management of Vrana. Further it is said that these four (i.e., Shanmoola, Astha Parigraahi, Pancha Lakshana and Shastya Vidhana) are to be thoroughly understood by the Vaidya before treatment, along with the Chikitsa Chatushpaadha as the treatment of ulcer becomes easier.

Dushta Vrana and wound correlation should be studied hand in hand to know the thorough interpretations of wound healing.

Prakshalan karma is the washing and the cleaning of the wound with ayurvedic prepared drug decoction or Kashayam. It helps in cleaning the wound from the dirt, infection, and germs and helps in the renewal of the cells herby hasting the wound healing procedure.<sup>5</sup>

Triphala kashayam taken from Bharat Bhaishajya Ratnakar Kashaya Prakaran describes this medicine as in water decoction form prepared with Haritaki, Amalaki and Bibhitaki. All ingredients are added to 16 parts of water, boiled and reduced to 1/4<sup>th</sup> part, filtered and used. It balances the Vaat and Kapha in the body.<sup>6</sup>

Jatyadi tailam prepared from Jatipatra, Neem, Patol, Karanj seeds, etc. ingredients mixed with sesame oil has been used extensively for healing wounds in piles, fissure, and fistula for generations due to its potent antiseptic properties which speeds up the healing process and shields the wound from germs.<sup>7</sup>

Patol Katurohinyadi kashay is a very potent ayurvedic decoction used in the treatment of anorexia, vomiting, and skin diseases, etc. This medicine is prepared from the herbs in Patoladi Gana of Ashtanga Hrudayam. Which consists of patol, katurohini, chnadana, madhusrava, guduchi, and patha. It is given with an adjuvant of honey for jaundice, psoriasis, allergic dermatitis, tinea infection, viral infection, and liver disease.<sup>8</sup>

Tiktak ghrita made with patol, nimba, katuka, darvi, duralabha, parpata, traymana, etc drug ingredients mixed with ghee with herb water decoction. Referred from ashtanga hrudayam chikitsa sthan 19/2-7, it is useful in snehakarma for the treatment of skin diseases, leprosy, visarpa, carbuncles, burning sensation, dizziness, itching, non-healing wound, wound with pus, sinus, and many other health conditions.<sup>9</sup>

## CONCLUSION

Based on this case study, it can be concluded that, Prakshalana Karma with Triphala Kashayam was found to be very effective in the management of Dushta Vrana. Triphala Kashaya prakshalana possesses high efficacy in Vrana Shodhana and Vrana Ropana with fine scaring without producing any adverse effect and it gives relief in signs and symptoms of Dushta Vrana. Thus, prakshalana karma along with internal medications quickens the process of wound healing and serves as an alternative herbal approach for management of Dushta Vrana.

## REFERENCES

1. Prof. Vasant C. Patil and Dr. Rajeshwari N.M, Sushruta Samhita Chaukhamba Publications, New Delhi, first edition 2018, , Volume 1, Sutra sthana , chapter 21, verse 40, p.284.
2. Shastri S. (Ed.) Madhav Nidanam of Sri Madhavakara with The “Madhukosh” Sanskrit Commentary, Sri Vijayarakshita & Srikanthadatta with The “Vidyotini Hindi Commentary & Notes, Part II, Uttardha, Sharira Vrana Nidanam: Chaukhamba Sanskrit Sanskrit Sansthan Publishers, Varanasi, 2005; 102: 42-7.
3. S. Das, textbook of surgery, Kolkata, 2020, wound healing ch.1, pg.no 1
4. Prof. Vasant C. Patil and Dr. Rajeshwari N.M, Sushruta Samhita Chaukhamba Publications, New Delhi, first edition 2018, Volume 2, Chikitsa sthana, chapter 1, verse 134, p.288.
5. Mashyal P, Bhargav H, Raghuram N. Safety and usefulness of Laghu shankha prakshalana in patients with essential hypertension: A self controlled clinical study. J Ayurveda Integr Med 2014; 5:227-35.
6. Peterson, C. T., Denniston, K., & Chopra, D. Therapeutic Uses of Triphala in Ayurvedic Medicine. Journal of alternative and complementary medicine (New York, N.Y.), 2017;23(8), 607–614. <https://doi.org/10.1089/acm.2017.0083>
7. Shailajan S, Menon S, Pednekar S, Singh A. Wound healing efficacy of Jatyadi Taila: in vivo evaluation in rat using excision wound model. J Ethnopharmacol. 2011 Oct 31;138(1):99-104. Doi: 10.1016/j.jep.2011.08.050. Epub 2011 Aug 30. PMID: 21907784.
8. Priya Puesh Pargotra, Abhishek Magotra. A study on the role of Patolkaturohni Kashyam, Ayyappalakera Tailam and diet in the management of Eka Kustha (Plaque Psoriasis). J Ayurveda Integr Med Sci 2019; 5:375-379
9. Vasu ray, S. Ramalingeswara rao, J Srinivasulu. Clinical Evaluation of Guggulu Tiktaka Gritha Matravasti and Pravalapisti in the Management of Asthi Kshaya w.s.r to Osteoporosis. International Journal of Ayurveda and Pharma Research. 2016;4(6):66-70

### Cite this article as:

Parvinder Singh *et al.* Effective management of Dushta vrana with prakshalan karma: A Case report. J Biol Sci Opin 2022;10(5): 77-80.  
<http://dx.doi.org/10.7897/2321-6328.105167>

Source of support: Nil; Conflict of interest: None Declared

Disclaimer: JBSO is solely owned by Moksha Publishing House - A non-profit publishing house, dedicated to publishing quality research, while every effort has been taken to verify the accuracy of the contents published in our Journal. JBSO cannot accept any responsibility or liability for the site content and articles published. The views expressed in articles by our contributing authors are not necessarily those of JBSO editor or editorial board members.