



Available online through

www.jbsoweb.com

ISSN 2321 - 6328

## Research Article

### ROLE OF AYURVEDIC MEDICINE AND LEECH THERAPY IN MANAGEMENT OF DEEP VEIN THROMBOSIS: A CASE STUDY

Kaur Rimpaljeet<sup>1\*</sup>, Chhabra Shailly<sup>1</sup>, Singh Amitabh<sup>2</sup>

<sup>1</sup>MD Scholar (Ay.), Department of Kayachikitsa, P.G. School of Ayurveda and Research, DBU, Mandigobindgarh, Punjab, India

<sup>2</sup>Professor, Department of Kayachikitsa, P.G. School of Ayurveda and Research, DBU, Mandigobindgarh, Punjab, India

\*Corresponding Author Email: dr.rimpal@gmail.com

Article Received on: 26/02/15 Accepted on: 08/04/15

**DOI: 10.7897/2321-6328.03218**

#### ABSTRACT

Panchakarma is a therapeutic way of eliminating toxic elements from the body. According to Sushruta, Panchakarma include five Shodhana (purification) process or therapies in which Raktamokshana (bloodletting) is one among them. Jalaukaavcharana (Leech therapy) is Shodhana type of treatment under raktamokshana. In Ayurveda, raktamokshana has been mentioned mainstay of treatment for raktapradoshajavikara. Deep vein thrombosis, or deep venous thrombosis, (DVT) is the formation of a blood clot (thrombus) within a deep vein, predominantly in the legs. Non-specific signs may include pain, swelling, redness, warmth, engorged superficial veins. D.V.T. formation typically begins inside the valves of calf veins where the blood is relatively oxygen deprived which activates certain biochemical pathways. The lifestyle of an individual can increase the risk for venous diseases. If a person is obese, or smoker, drinks excessive amount of alcohol, or consume fatty foods, it can lead to blood thickening and obstruction of the vessels by fatty deposits or plaque formation. This is the case presentation of 47 years old male patient had a history of D.V.T., having complaints of pain and numbness in left leg since 8 months. A Colour Doppler Ultrasound was positive for D.V.T. The Jalaukaavcharana was done weekly along with oral medication for total duration of 30 days with continuation of the previous medication. The patient got relief in clinical sign and symptoms of D.V.T.

**Keywords:** Panchakarma, Raktamokshana, Deep vein thrombosis, Jalaukaavcharana.

#### INTRODUCTION

Deep vein thrombosis (DVT) is a silent killer.<sup>1</sup> It is the third most common vascular disease, after ischemic heart disease and stroke.<sup>2</sup> The mechanisms underlying DVT, known as Virchow's triad, are venous stasis, hypercoagulability and endothelial injury.<sup>3</sup> Mainly two types of venous thrombosis are seen, superficial vein thrombosis (Thrombophlebitis) and deep vein thrombosis (Phlebothrombosis). Out of two, DVT is of more importance as this can result in life threatening condition like pulmonary embolism due to dislodgement of thrombus loosely attached to vessel wall.<sup>4</sup>

Known risk factors for development of DVT during medical and surgical hospitalizations include congenital factors (i.e. hereditary thrombophilia like Factor V Leiden, prothrombin deficiency) and acquired factors (advanced age, obesity, surgery, trauma, neoplasm, heart, kidney and bowel diseases, estrogen hormone therapy, pregnancy and postpartum period, tamoxifen, dehydration, immobilization).<sup>5</sup> Venous thrombosis is often asymptomatic and is clinically manifested in 40 % or less cases. It mainly represent as aching pain which is aggravated by muscular activity at the site of thrombus. Swelling is minimal at dependant part along with tenderness in the region of the vein. The calf is most frequent site of thrombosis. Treatment of DVT is mainly aimed at reduction the propagation of thrombus, to limit the damage to the venous valves and to reduce the probability for pulmonary embolism. Modern treatment of established cases of DVT include bed rest, elevation of legs, elastic stockings and use of drugs like heparin, coumarin derivatives (warfarin), fibrinolytic drugs (streptokinase) and

aspirin etc.<sup>6</sup> As per Ayurveda, there is no direct reference of any such disease, but causes, sign and symptoms of DVT resemble various conditions in Ayurveda. One of them is siragata vata in which there is pain in the region of sira along with narrowing or obstruction in the lumen of sira.<sup>7</sup> Another condition called raktaavritta vata has been described with symptoms of pricking pain, hyperaesthesia and numbness of the area affected.<sup>8</sup> As far as aetiology of the disease is concerned many factors mentioned in nidana of vatarakta like achankramansheelinam (prolonged sedentary period), abhigata (trauma), sthulata (obesity) etc<sup>9</sup> are also predisposing factors for DVT. In such condition of vata affecting the sira, Acharya Sushruta has exclusively mentioned the treatment regime which includes raktamokshana.<sup>10</sup> Acharya Vagbhatta has mentioned that leech can be applied in the area where blood is clotted.<sup>11</sup> Acharya Charka has enumerated blood related disorders and their treatment by various type of bloodletting.<sup>12</sup> As these are basically raktapradoshajavikaras so raktamokshana was planned for this patient.

#### Case Report

A male patient of 47 years of vatapittaja prakriti, Sikh by religion, living in Mandigobindgarh, Punjab, India approached OPD of DBACH and registered with Cr.NO.-3556/459 on Feb 4<sup>th</sup> 2013. Patient was asymptomatic 8 months ago. 8 months back, he developed pain in the left leg. He consulted a nearby physician but had no relief. Later, his condition get worsened and he was not able to bear weight on the left leg and unable to walk for which he visited Government Rajinder Hospital Patiala, India and he was suggested to go for colour Doppler study for both

legs. The colour Doppler suggestive of Ac. Thrombosis in left femoral vein and partial recanalization of thrombus in right femoral vein (Jan 19<sup>th</sup> 2013). Tab. Warfarin 2 mg 1BD, Tab. Monotrait 20 mg 1BD, Tab. Dolo-650 mg 1BD for 20 days was given to patient but he did not get any relief with this treatment. Hence, he approached to DBACH, Mandigobindgarh, Punjab, India for better management. He come to us with complaints of Pain in left leg since 8 months, Numbness in both legs since 8 months, not able to walk properly, Slight swelling over the left lower leg. According to patient statement, it was found that pain was constant, severe aching in nature, not radiated to any other part, aggravated on standing for long time and relieved by elevation of left leg. He had no history of Hypertension, diabetes mellitus, trauma, previous surgery. On examination, in upper thigh and calf region tenderness was present, in left lower leg redness and oedema was present. Homan's Sign (dorsiflexion of foot may cause pain in calf region) was positive. Moses' sign (when the calf muscle is compressed forwards against the tibia, but not when the calf muscle is compressed from side to side) was positive. All the laboratory investigations were normal excluding Prothrombin time-15 sec, Prothrombin Ratio-1.07, I.N.R.-1.16. In Urine examination, albumin was traceable. The patient was treated with both internal and external medications for four weeks. The details of treatment are given below:-

**Internal medications was**

- Ekangaveer Rasa 150 mg 1 Tab. BD,
- Mahayograj guggulu 325 mg 1 Tab. BD,
- Maharasnaadi Kwatha 60 ml. BD.

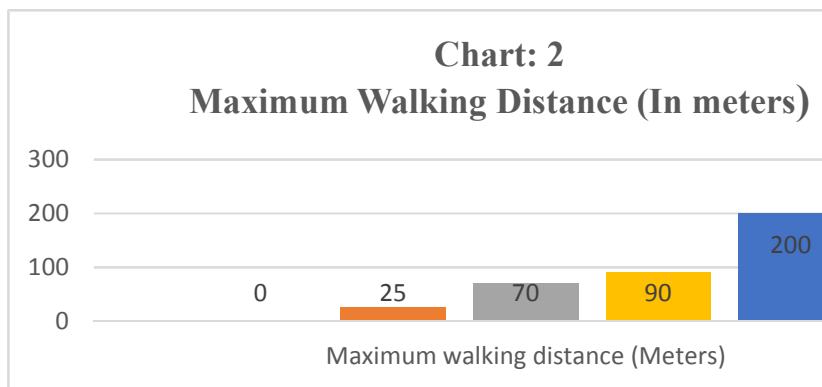
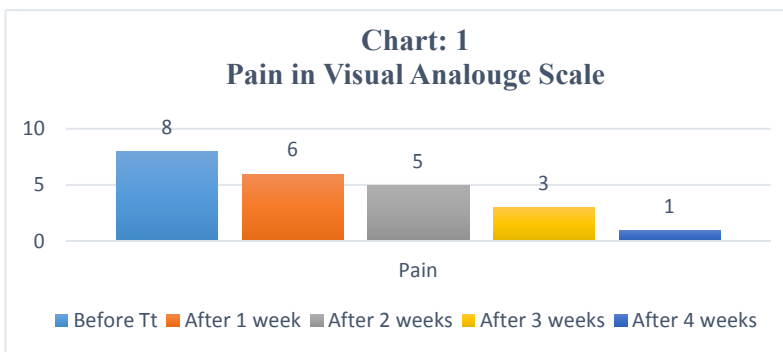
**External medications was**

- Abhyanga with Vishgarbh Tail.
- NadiSawedana with Rasanasantak Kawath.
- Jalaukaavcharana- started on Feb 13<sup>th</sup> 2013 and repeated after every 7<sup>th</sup> day.

Total treatment period was four weeks. On the basis of visual analogue scale (VAS), patient was assessed weekly. Pain gradation was as follow

0-1	No Pain
2-3	Mild
4-5	Uncomfortable
6-7	Distressing
8-9	Intense
10	Worst Possible

As we observed in VAS, before treatment pain grade was 8. After 7 days of treatment pain grade comes down 6, further on the completion of 2<sup>nd</sup> week, 3<sup>rd</sup> week and 4<sup>th</sup> week pain grade was 5, 3 and 1 respectively (Chart 1). Before treatment patient was having swelling on left leg which later completely subsided in two weeks. Gradual improvement in walking distance of patient was as following i.e. initially he was not able to walk, after the treatment of one week he was able to walk of the distance 25 meters and later after the treatment second, third week and four weeks he was able to walk up to the distance 70 meters, 90 meters, 200 meters respectively (Chart 2). Patient was suggested to continue treatment and advise to attend the OPD after one month. Patient was observed that he has no problem in walking up to any extent.



Charts: Observations of different parameters before and during treatment

## RESULT

After the completion of therapy patient was in supervision up to 3 months without intervention follow up and it was observed that the patient is symptomless and cured.

## DISCUSSION

The purpose of Ayurveda is to maintain the health of healthy individual and treat the patient.<sup>13</sup> Basically the Ayurveda is the complete science of life, which has various drugs and techniques for treatment of mankind. Raktamokshana is one of the biggest innovations in the field of Ayurveda, which also includes the Leech therapy in the form of ashstrakrita raktamokshana.<sup>14</sup> It is safe, painless and highly effective. Once the leech's bites a target, the saliva enters the puncture site along with enzymes and compounds responsible for all the positive effects. Because of anticoagulation agents the blood becomes thinner, allowing it to flow freely through the vessels. The anti-clotting agents also dissolve clots found in the vessels, eliminating the risk of them travelling to the other parts of the body and blocking an artery or vein. The vasodilating agents help widen the vessel walls by dilating them and this causes the blood to flow unimpeded too. Patients who suffer from pain and inflammation will feel relief from the anti-inflammatory and anaesthetic effect of the leech's saliva.

### Anti-coagulating effect of leeches

The leech's saliva contains enzymes and compounds that act as anticoagulating agent. The most prominent of these anticoagulation agents is hirudin which binds itself to thrombins, thus effectively inhibiting coagulation of the blood. Another compound that prevents coagulation is calin. This on the other hand work as an anticoagulant by prohibiting the von Willebrand factor to bind itself to collagen, and it is also an effective inhibitor of platelet aggregation caused by collagen. The saliva of leech also contains factor Xa inhibitor which also block the action of the coagulation factor Xa.<sup>15</sup>

### Clot dissolving effect of leeches

The action of destabilase is the break up any fibrins that have formed. It also has a thrombolytic effect, which can also dissolve clots of blood that have formed.

### Anti-inflammatory effect of leech

Bdellinsis; a compound in the leech's saliva; that acts as anti-inflammatory agent by inhibiting Trypsin as well as plasmin. It also inhibits the action of acrosin. Another anti-inflammatory agent is the eglins.<sup>16</sup>

### Vasodilating effects of leech

There are 3 compounds in the leech's saliva that act as a vasodilator agent, and they are the histamine-like substances, the acetylcholine and the carboxy-peptidase A inhibitors. All these act to widen the vessels, thus, causing flow of blood of the site.

### Bacteriostatic and Anaesthetic effect of leech

The saliva of leeches also contains anaesthetic substances which relieve pain on the site and also bacteria inhibiting substances which inhibit the growth of bacteria.<sup>17</sup> There were no adverse events throughout the management. The mode of treatment was found to be cost effective, safe and easy to implement. So

Jalaukaavcharana (hirudotherapy) is safe and effective method in management of D.V.T. than modern treatments.<sup>18</sup>

## CONCLUSION

In present study, the leech application in case of DVT is found to be effective. Leech therapy is beneficial in reduction of pain, swelling, tenderness in the patient of DVT. With the help of leech therapy we can improve the quality of life of the DVT patients. We can avoid the hazards of prolong use of heparin like drugs by using leech therapy. In addition to these benefits, this method is cost effective, less time consuming.

## REFERENCES

1. Autar R. Deep vein thrombosis: the silent Killer. Quarry Books. Mark Allen Publishing. Wiltshire; 1996.
2. Anands SS, Wells PS, Hunt D *et al*. Does the patient have deep vein thrombosis? Journal of American Medical Association 1998; 279(14): 1094-1099. <http://dx.doi.org/10.1001/jama.279.14.1094>
3. Lowe GD. Virchow's Traid revisited: abnormal flow. Pathophysiol Haemost Thromb 2003; 33: 455-457. <http://dx.doi.org/10.1159/000083845>
4. Das Somen. 7<sup>th</sup> chapter, Examination of Varicose Vein. A Manual on Clinical Surgery. Kolkata: Dr S Das Publication; Edition 7<sup>th</sup>; 2008. p. 78.
5. Lowe GD. Virchow's Traid revisited: abnormal flow. Pathophysiol Haemost Thromb 2003; 33: 455-457. <http://dx.doi.org/10.1159/000083845>
6. Das Somen. Diseases of Veins. A Concise Textbook of Surgery. Kolkata: Dr S Das Publication; Edition 6<sup>th</sup>; 2010. p. 274.
7. Shastri Kaviraj Ambikadutt. Nidana Sthana, Vatavyadhinidanaadhyaya. Sushruta Samhita Ayurveda Tattva Sandipika Hindi commentary Part I. Varanasi, Chaukhamba Sanskrit Sansthan; Edition Reprint; 2007. p. 230.
8. Murthy K. Nidana Sthana, Vatavyadhi nidanaadhyaya. Astang Hridya, English translation Part-II. Varanasi: Krishnadas Academy, Edition 2<sup>nd</sup>; 1995. p. 150.
9. Shastri KN, Chaturvedi GN. Chikitsa Sthana, Vatashonitachikitsaadhyaya. Charaka Samhita, Vidyotini Hindi Commentary Part-II. Varanasi: Chaukhamba Bharti Academy; Edition Reprint; 2013. p. 820.
10. Shastri Kaviraj Ambikadutt. Chikitsa Sthana, Vatavyadhichikitsaadhyaya. Sushruta Samhita Ayurveda Tattva Sandipika Hindi commentary Part I. Varanasi, Chaukhamba Sanskrit Sansthan; Edition Reprint; 2007. p. 26.
11. Tripathi Ravidatta. Sutra Sthana, Jalauka vidhiadhyaya, Astanga Samgraha Saroj Hindi commentary Part I. Delhi: Chaukhamba Sanskrit Pratisthan; Edition Reprint; 2003. p. 604.
12. Shastri KN, Chaturvedi GN. Chikitsa Sthana, Vatavyadhichikitsaadhyaya. Charaka Samhita, Vidyotini Hindi Commentary Part-II. Varanasi: Chaukhamba Bharti Academy; Edition Reprint; 2013. p. 803.
13. Tripathi Brahmanand. Sutra Sthana, Dashmahamuliyamadhyaya. Charaka Samhita Charaka Chandrika Hindi commentary Part-I. Varanasi: Chaukhamba Surbharti Prakashana; Edition Reprint; 2003. p. 565.
14. Tripathi Ravidatta. Sutra Sthana, Jalauka vidhiadhyaya. Astanga Samgraha Saroj Hindi commentary Part-I. Delhi: Chaukhamba Sanskrit Pratisthan; Edition Reprint; 1999. p. 599-604.
15. Ameen MM. Niamath's Herbal Unani Med. An International Health Magazine; V.P.S. Printer; Chennai 2013; 14(7): 24.

16. <http://admonitus.ro/?m=20140527>; 2015.
17. [www.leechestherapy.com/benefits\\_and\\_effects.php](http://www.leechestherapy.com/benefits_and_effects.php); 2015.
18. [herbalnet.healthrepository.org/bitstream/123456789/2493/1/Research%20protocol%20for%20traditional%20health%20science.pdf](http://herbalnet.healthrepository.org/bitstream/123456789/2493/1/Research%20protocol%20for%20traditional%20health%20science.pdf); 2015.

**Cite this article as:**

Kaur Rimpaljeet, Chhabra Shailly, Singh Amitabh. Role of Ayurvedic medicine and leech therapy in management of deep vein thrombosis: A case study. *J Biol Sci Opin* 2015;3(2):87-90 <http://dx.doi.org/10.7897/2321-6328.03218>

Source of support: Nil; Conflict of interest: None Declared